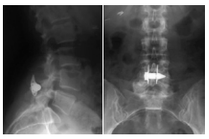

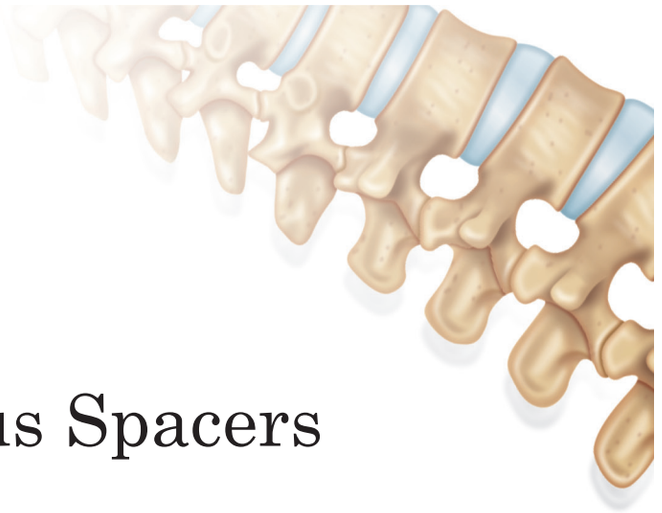

54 Interspinous Spacers

Joshua Abrams, James Zucherman

INTRODUCTION

Anatomy

Lumbar spinal stenosis is a narrowing of the spinal canal leading to a reduction in space available for neural structures and their blood supply. The direct narrowing is due to a constellation of pathologies including thickened lamina, hypertrophied buckled ligamentum flavum, spondylolisthesis, disk bulge and facet arthrosis. In the degenerative cascade as the disk becomes dehydrated, the disk space collapses. Loss of disk height leads to annular bulging and infolding of the ligamentum flavum. As the disk space collapses, the distance between the spinous processes in the posterior column, shortens.[1] Additionally, the posterior facet joints assume a larger load transfer as the disk degenerates leading to facet arthrosis (i.e. osteophyte complex, facet cysts). These degenerative alterations reduce the area of the canal. In the subarticular zone, these changes lead to compression of the traversing nerve root. Compression can also occur within the neuroforamen causing compression of the exiting nerve root. The anteroposterior diameter of the foramen is reduced by the bulging of annulus anteriorly and the hypertrophic facets posteriorly. The foraminal height is reduced by disk dehydration and loss of disk height. This is effectively known as "up-down" stenosis. The foraminal zone can become further stenotic if the segment has a listhesis, altering the normal concentric keyhole configuration.

SURGICAL INDICATIONS

Neurogenic intermittent claudication (NIC) is the most common presenting symptom of spinal stenosis. This is a posture-dependent complaint that typically affects patients greater than 50 years of age. Patients present with pain or numbness extending into the buttocks, thighs and/or legs brought on by walking or standing in an erect posture. These postures place the spine in extension and with the aforementioned degenerative changes lead to canal narrowing. Patients frequently receive relief of their symptoms with a forward flexed posture, known as the "shopping cart sign." Penning and Wilmink[2] reported on the phenomenon in which a flexed posture increases the spinal canal diameter and effectively reduces the compression on the neural structures (Figs 1A and B).

This presentation led to the genesis of the concept of keeping individual spinal segments in

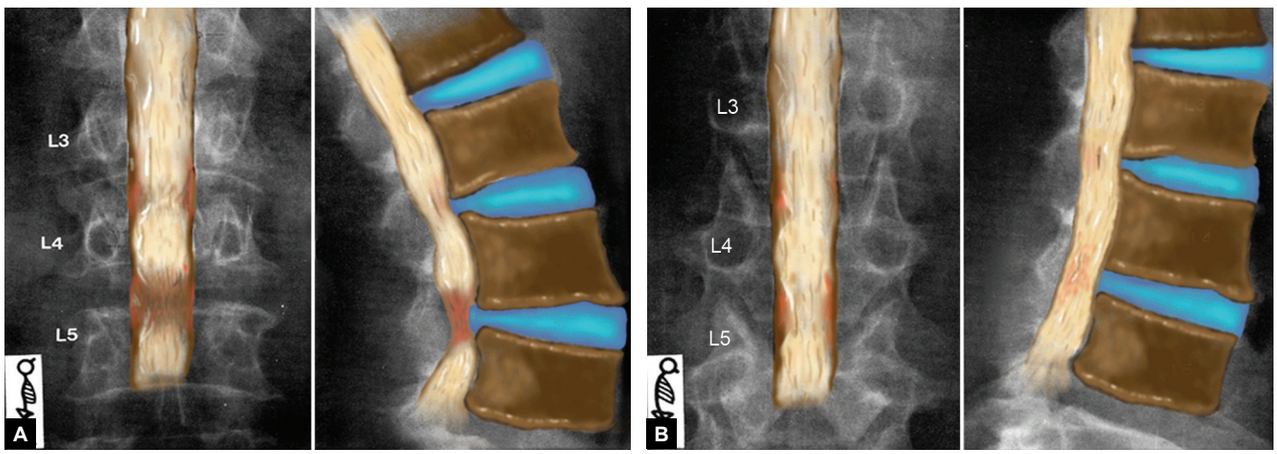

Figs 1A and B: (A) Radiographic illustration depicting focal spinal stenosis with the lumbar spine; (A) In an upright neutral position; (B) In flexion

flexion and limiting the amount of local extension at the site of greatest stenosis. To achieve this, interspinous process devices (IPDs) are placed in between the spinous processes, which act as lever arms of the entire spinal motion segment. Placement of IPDs leads to focal flexion of the spinal segment, keeping the ligamentum flavum tight and effectively increasing the spinal canal diameter.[3] Zucherman et al. demonstrated the placement of an IPD which is superior to non-operative treatment for NIC at 1, 2, and 4 years postoperatively.[4-6] The only interspinous process decompression device approved by the United States Food and Drug Administration for use in the US is the X-STOP (Medtronic, Inc, Minneapolis, MN, USA). Other implants have been used routinely outside the US and some are currently approved for clinical trial. In a magnetic resonance imaging (MRI) cadaver study, Richards et al. reported that the X-STOP increases the neural foraminal area by 26% and the spinal canal area by 18% during extension. In addition, foraminal width is increased by 41% and subarticular diameter by 50% in extension (Figs 2A to D).[7] Other interspinous implants have been developed including: Device for intervertebral assisted motion (DIAM); Medtronic Sofamor Danek, Memphis, TN), Wallis Stabilization System (Zimmer, Bordeaux, France), and COFLEX [Paradigm Spine, New York, NY (Fig. 3)]. Each implant has detailed its own indications, but generally, the goals are rather consistent.[8,9]

Placement of X-STOP is indicated in patients, whose symptoms are exacerbated in extension and relieved in flexion, exhibiting NIC. Patients who have failed a trial of conservative management (usually up to 6 months) are the most typical candidates. Spondylolisthesis up to a Meyerding Grade 1 is indicated; unstable segments or segments greater than Meyerding Grade 1 are contraindicated. IPDs may also off-load the facet joint and provide dynamic support and help restore more normal kinematics. IPDs also decrease intradiscal pressure by acting as load sharing devices without altering the spinal biomechanics.[10,11] To date, no prospective clinical outcome of studies have demonstrated proven indications for these implants, with the exception of the X-STOP.[3,4] Understanding of the theoretical advantages and clinical experience guides a surgeon's preference and use. X-STOP and DIAM may also be utilized in patients who are unable to undergo general anesthesia because of medical comorbidities. Additionally, a laminotomy can be performed in conjunction with IPD placement, if the surgeon prefers direct decompression. Placement of Coflex, as discussed later, necessitates either

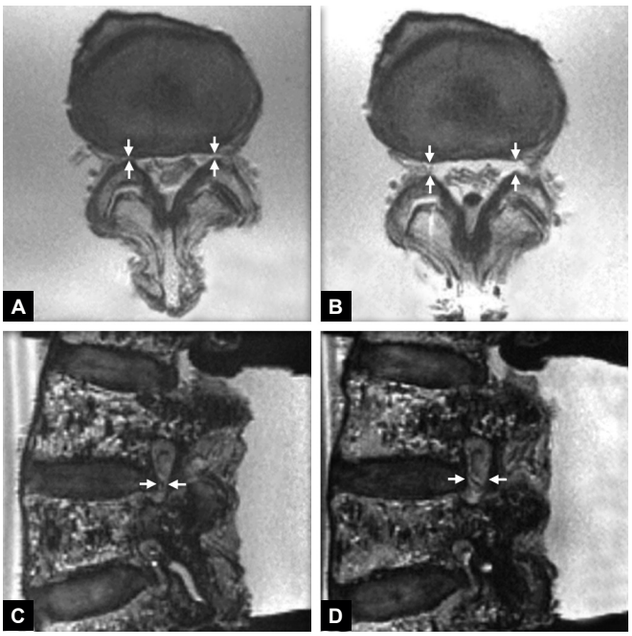

Figs 2A to D: (A and B) Axial; (C and D) Pedicular plane magnetic resonance imaging of a specimen in the extended position with and without the implant. The axial slices were taken through the middle of the L3/4 intervertebral disk. A is an intact specimen in the extended position. Notice the narrow subarticular diameter between the anterior facet and posterior annulus (arrows). B is of the same specimen with an X-STOP placed between the L3 and L4 spinous processes. Notice the subarticular diameter in the implanted specimen (arrows). C is of the intact specimen in the extended position, and D is of the same specimen in the extended position with the implant placed at L3/4. The foraminal area and width are noticeably greater in the implanted specimen (arrows).
Source: Adapted from Richards, et al. The treatment mechanism of an interspinous process implant for lumbar neurogenic intermittent claudication. Spine 2005

Implant	Walls	X-STOP/X-STOP^{PX}	Coflex (Interspinous U)	DIAM
Company	Abbott spine	Kyphon Inc.	Paradigm spine	Medtronic
Launch	2002 (new)	2002	1994 (The U)	2001
Developer	Senegas J	St Francis Inc.	Samani J	Taylor J
FDA Status	Approved for clinical trial	Approved for clinical use	Approved for clinical trial	Approved for clinical trial
Composition	Blocker—PEEK	Titanium alloy body and PEEK spacer (X-STOP^{PX})	Titanium alloy	Silicone core with polyester sleeve
Technique	Removal of supraspinous ligaments necessary	Preserves supraspinous ligament	Removal of supraspinous ligaments necessary	Preserves supraspinous ligament
Implant				

FDA indicates Food and Drug Administration; PEEK, PEEK, polyether ether ketone

Fig. 3: 'Relevant features of the interspinous devices
Source: Kabir et al. Lumbar Interspinous Spacers

a unilateral or bilateral laminotomy. Coflex can also function to augment an interbody fusion (i.e. COFLEX-F).

IMPLANTATION OF SPECIFIC SURGICAL TECHNIQUE

X-STOP and X-STOP-PK

Placement of the X-STOP is performed with the patient in the right lateral decubitus position (Fig. 4A). This procedure can be completed under local anesthetic with light intravenous sedation or under general anesthesia (If a general anesthetic is performed, then the patient is positioned prone with the hips flexed). With the patient placed under light sedation, the operative level is confirmed under fluoroscopy. Local anesthetic is placed in the skin, subcutaneous tissues, fascia and on the posterior rami. To accurately identify the length of incision, needles can be placed at the caudal and cephalad ends of the proposed incision.

For placement of a single level implant, a 4–8 cm mid-sagittal incision is completed at the appropriate level. A Cobb elevator is used to sweep the subcutaneous tissues from the dorsal fascia. The posterior lumbodorsal fascia is incised on either side of the spinous processes taking care to preserve the supraspinous ligament. The spinal musculature is then subperiosteally elevated off the spinous processes and transitioning lamina bilaterally.

At this point, the participating patient is asked to curl up and flex their spine to maximal capability. The interspinous space is palpated. If the interspinous ligament is overly redundant, a portion of it can be removed with a #12 blade. A small curved dilator is then inserted through the ventral-most margin of the interspinous space from right-to-left (Fig. 4B). Lateral fluoroscopy confirms a ventral-most position within the correct interspinous space. The small dilator is followed by placement of the larger dilator. Care is taken to maintain a finger opposite of the insertion site during exchange. After the large dilator is removed, the distractor is inserted and utilized to distract the spinous processes (Fig. 4C). Fully flexing the lumbar spine of the participating patient helps with optimal distraction. The distraction can be verified fluoroscopically (Fig. 4D). The distractor has a gauge on it to measure the appropriate size for implant. The X-STOP is then implanted from right-to-left, again with the finger placed on the left side to locate and guide the implant into proper position (Fig. 4E). The implant is inserted until the right wing is flush

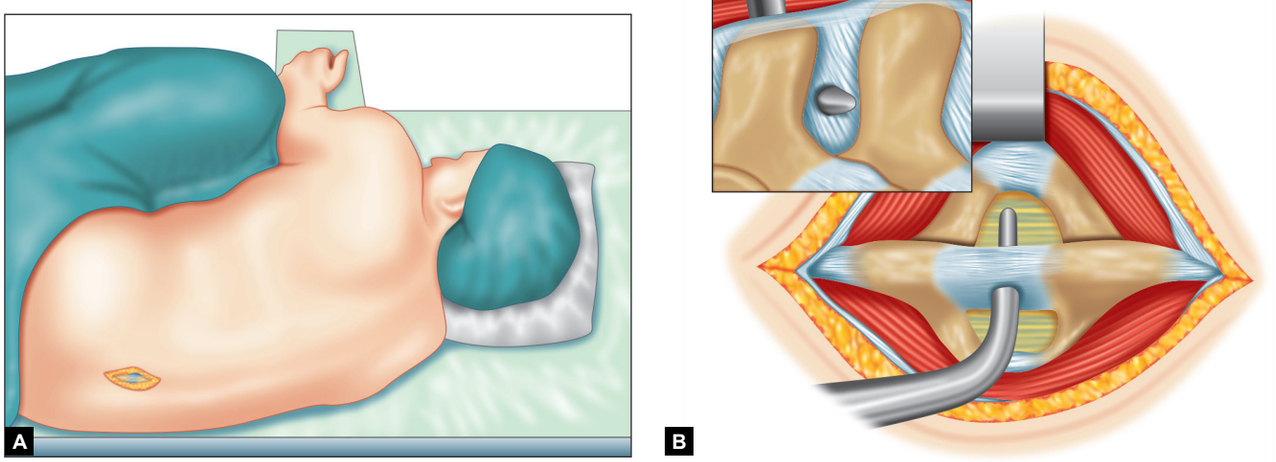

Figs 4A and B

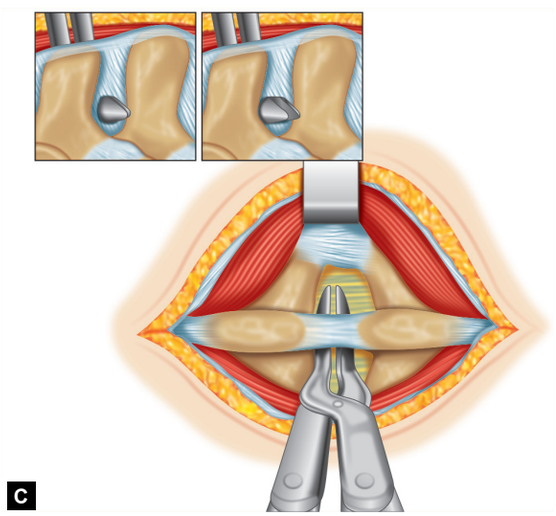

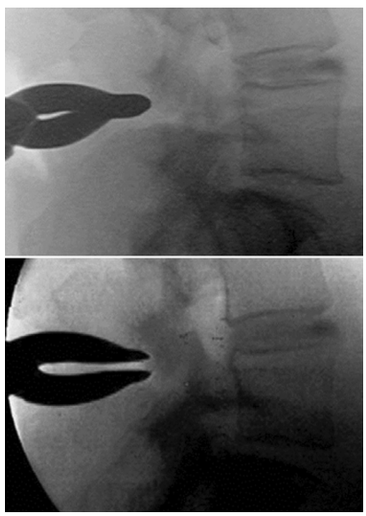

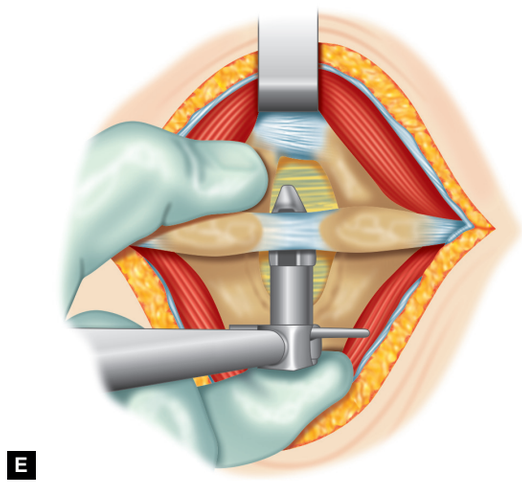

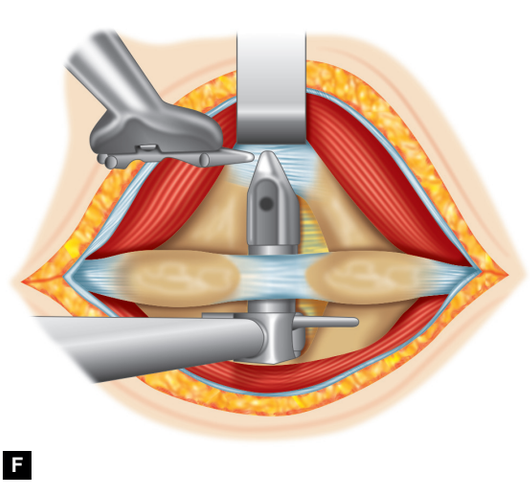

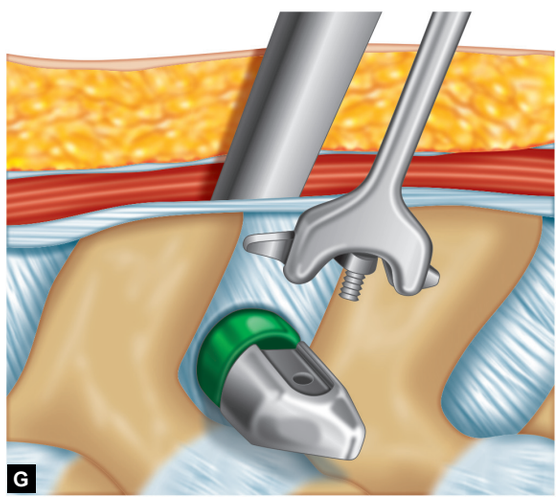

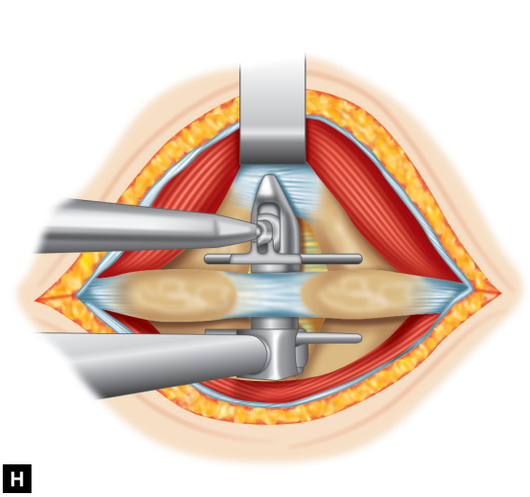

Figs 4C to H

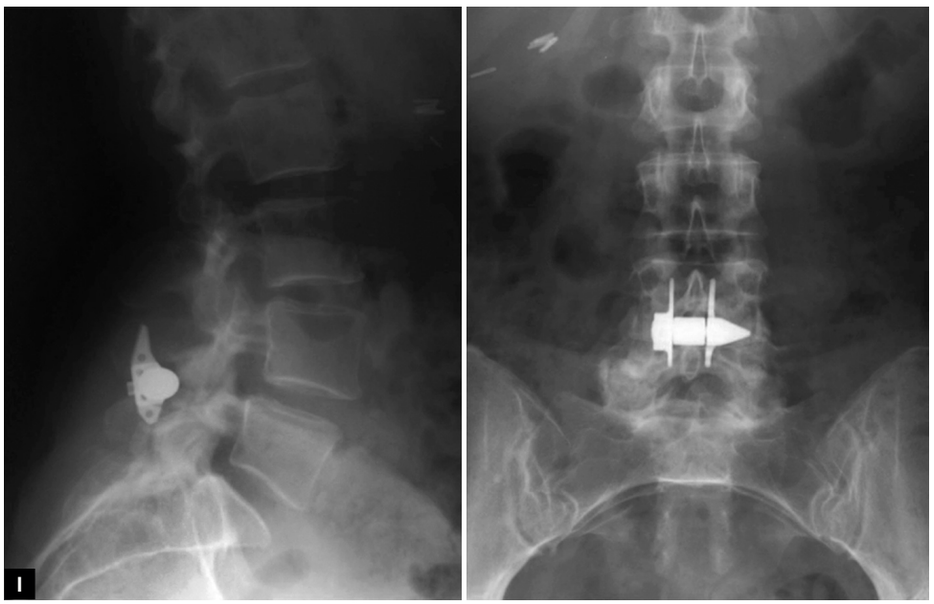

Figs 4A to I: X-STOP Technique. (A) A midline incision is made with the patient in a flexed rightlateral decubitus position; (B) A small dilator is placed through the interspace from right-to-left; (C) After a large dilator is removed, the distractor is placed through the interspinous space; (D) Fluoroscopic confirmation of the sizing distractor; (E) A finger helps guide the insertion of the implant from right-to-left; (F) The right wing should be flush as the universal wing is inserted; (G) The screw hole is visualized and the universal wing is inserted; (H) The two wings are approximated medially (not shown), and the universal wing screw is tighted with a torque-limiting screwdriver; (I) Final radiographic position

Source: Adapted from Christie SD, Song JK, Fessler RG. Dynamic Interspinous Process Technology. Spine 2005

against the spinous processes. The universal screw hole on the implant is visualized on the left side. The universal wing on a long driver engages this screw hole and is inserted loosely (Figs 4F and G). The two wings are then approximated medially, and the "universal wing screw" is tightened with a torque-limiting driver (Fig. 4H). Final fluoroscopy images confirm positioning (Fig. 4I). A drain is typically recommended. A careful layered closure is performed. The two fascia incisions are approximated and sutured to the cuff of midline fascia and supraspinous ligament, separately. The skin is closed in usual fashion.

Device for Intervertebral Assisted Mobility (DIAM)

Either local or general anesthesia can be performed. Local anesthesia is reserved for single level implants. General anesthesia is utilized for multilevel cases or when implantation is performed in conjunction with a laminotomy. Once anesthetized, the patient is placed in a prone position to reduce the normal lordotic contour of the lumbar spine. Fluoroscopy is used to localize the appropriate interspinous space.

A 4 cm midline incision is performed. A Cobb elevator is utilized to sweep the subcutaneous tissues away from midline. Parallel incisions are made on either side of the spinous process through the lumbodorsal fascia, preserving the supraspinous ligament. The paraspinal musculature is then subperiosteally elevated from the spinous processes and lamina both above and below the interspinous space (Fig. 5A). The interspinous ligament is then resected with a rongeur to the level of the ligamentum flavum (Fig. 5B). The interspinous distractor is then placed as ventral as possible in the interspace (Fig. 5C). Distraction is then placed between the two spinous processes to achieve

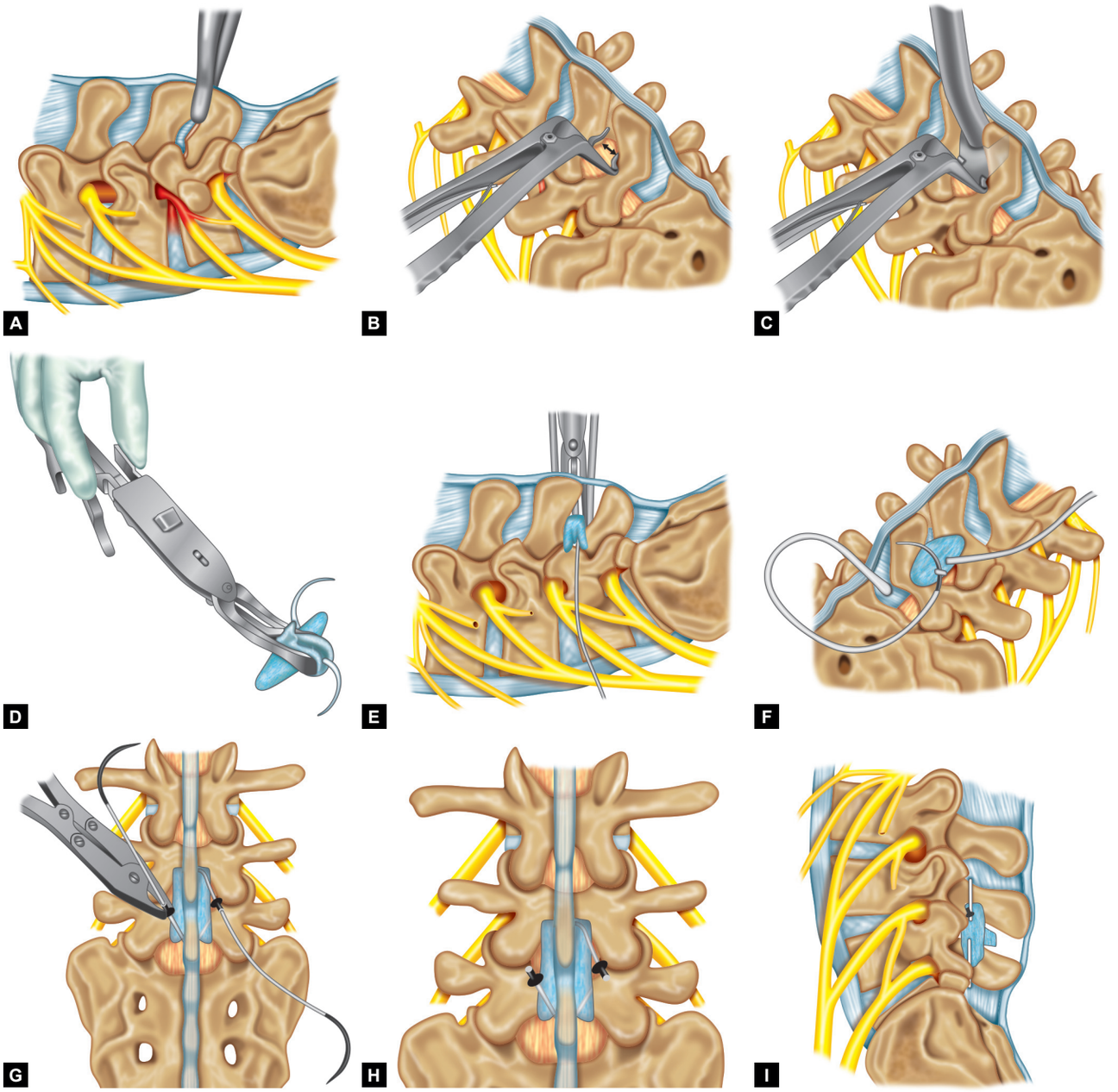

Figs 5A to I: DIAM technique. (A)The interspinous space is prepared by removing the interspinous ligament; (B) Distraction is applied until the appropriate degree of tension is achieved; (C) A series of trials are used to select the proper size implant; (D) To prepare the implant for insertion, the implant is loaded into the inserter. The wings of the implant will fold as the inserter flanges are compressed; (E) Overdistraction may be applied to facilitate insertion of the implant. The DIAM-device is passed through the interspace until the jaws of the inserter are in contact with the corresponding spinous processes. The contralateral tether is also passed through the interspace simultaneously; (F) The tethers are passed around the adjacent spinous processes and then through the loop on the side of the implant; (G) A crimp tool secures the crimps while applying longitudinal tension; (H and I) Final position of the implant.

Source: Adapted from Medtronic Sofamor Danic DIAM Spinal Stabilization System Surgical Technique guide

the optimal tension of the supraspinous ligament. If a mechanical block to distraction is encountered, interlaminar bony bridges can be resected. Additionally, if the surgeon opts to directly decompress the segment, a laminotomy and/or medial facetectomy can be performed at this point.

A series of trials can measure the appropriate size for the DIAM system device (Fig. 5D). The trials provided are 8 mm, 10 mm, 12 mm and 14 mm. To prepare the implant for insertion, the wings of the implant are folded and the implant is compressed (Fig. 5E). With distraction in place, the implant is inserted (Fig. 5F). As the implant is advanced, the wings are deployed to allow the implant to recover its original 'H' shape. The DIAM implant is secured in place with two tethers that are passed around the adjacent spinous processes and fixed into respective loops on the side of the implant (Fig. 5G). Slide the crimps onto the tethers. Apply longitudinal traction to the tethers and compress the crimp tool overlying the crimps to fasten the implant (Figs 5H and I). The excess portion of the tethers is then removed. A drain may be placed, but this is up to the surgeon's preference and experience. The lumbodorsal fascia is approximated and sutured to the midline fascia and supraspinous ligament. The skin is closed in the surgeon's usual fashion.

WALLIS

After a general anesthesia is administered, the patient is placed in a prone position with pads strategically placed to reproduce a neutral position of physiologic lumbar lordosis to best optimize the effect of the implant. Fluoroscopic localization identifies the segment of interest. At this point a 3–4 cm incision is made. With similar technique as previously stated with the other IPDs, the lumbodorsal fascia is incised on each side of the spinous process. Subperiosteal dissection allows access to the interspinous space. The supraspinous ligament is detached from the two spinous processes and retracted laterally without sectioning. The interspinous space is localized with a finger. The most ventral portion of the interspinous ligament is then resected. The bony junction between the laminae and spinous processes may also be trimmed to help position of the implant as ventral as possible.

The interspace is localized and a series of trial spacers are placed with the use of the "trial spacer holder" (Figs 6A and B). An interlaminar distractor can be placed between the adjacent lamina to provide adequate distraction to achieve optimal distraction and trial spacer placement. The interlaminar distractor should be removed before testing the stability of the "trial spacer" in the interspinous space. Either the interlaminar distractor or spacer holder can maintain the appropriate distraction for placement of the final implant (Fig. 6C). Implant sizes available in range from 8 mm to 16 mm.

Once the PEEK spacer is placed, the two flat woven polyester bands are passed around the corresponding spinous processes. The "band passer" helps to facilitate the passing of the bands through the adjacent interspinous ligament with minimal disruption (Figs 6D and E). Once passed, the surgeon should verify that the band is flat against the spinous process without being twisted. The "fastening clip" is aligned in its final position with the arrow pointing towards the center of the spacer. The bands are threaded through a "fastening clip" (Fig. 6F). The "fastening clip" is then rotated 360° counterclockwise (Fig. 6G). The "clipping forceps" is inserted in the opening of the spacer closest to the clip involved. The forceps must be inserted in the spacer opening as deeply as possible to ensure simultaneous introduction of all four stubs on the clip into the corresponding slots on the spacer (Fig. 6H). A torque measuring "tightener" and "tightener guide" are mounted onto the implant. A clockwise motion tightens the "fastening clips" to appropriately tension the bands around the spinous processes (Fig. 6I). Finally, a "finishing ring" is slipped over the ends of each band and firmly

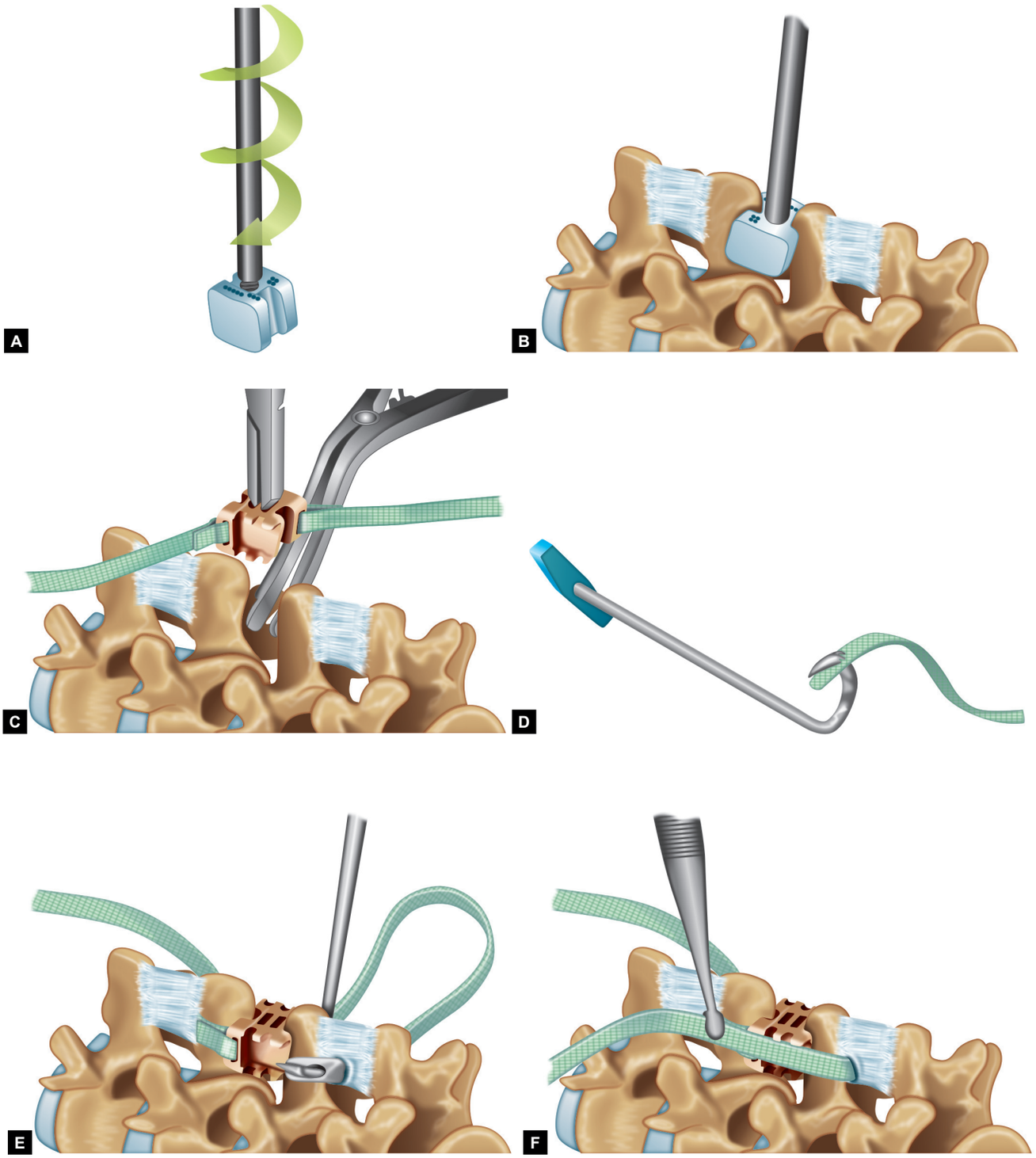

Figs 6A to F

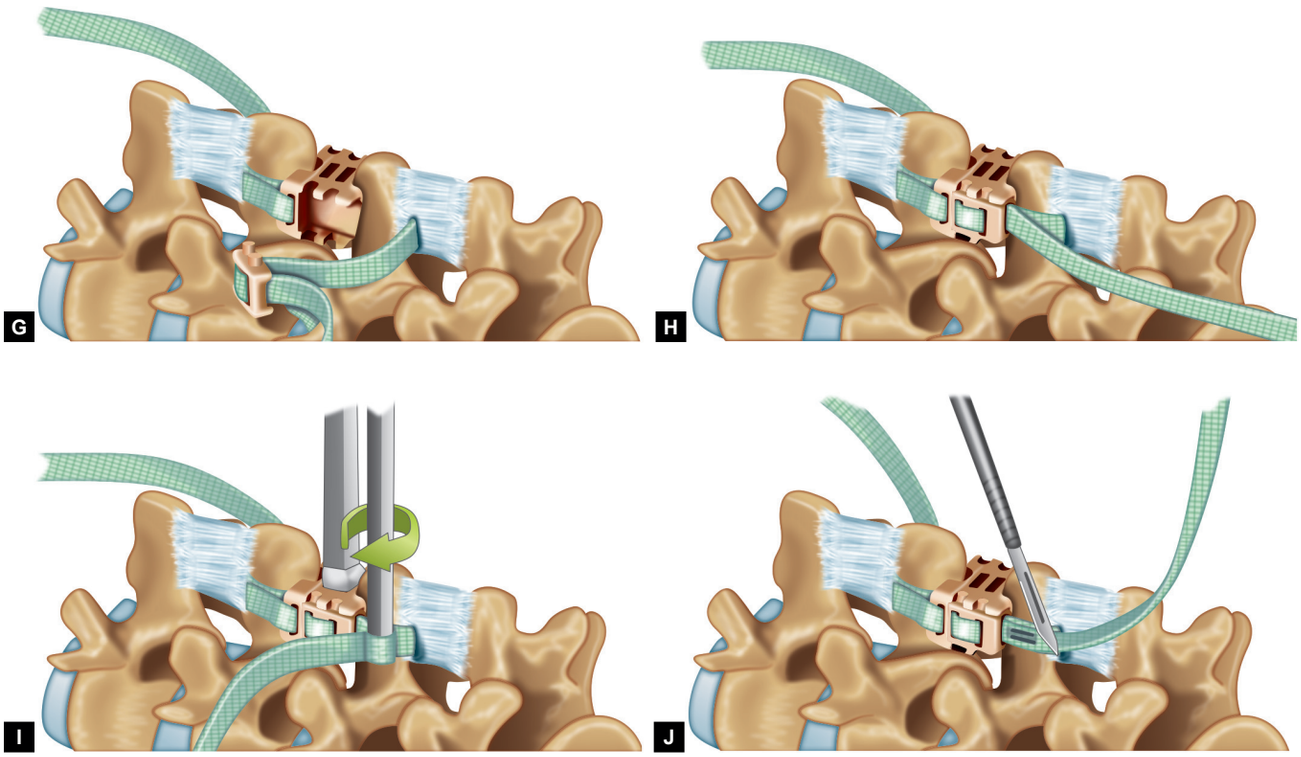

Figs 6A to J: Wallis Technique. (A and B) The adequate size of the implant is determined by placing different trial spacers; (C) Placement of the final implant can be facilitated by the interlaminar distractor; (D) The band is engaged in the slot at the tip of the band passer; (E) The bands are passed through the adjacent interspinous ligaments; (F) The bands should be flat against the spinous processes; (G) The bands are threaded through the clip; (H) The clip is rotated 360° counterclockwise and reduced into the spacer with the clipping forceps; (I) The bands are pulled taut and the final tighteners are turned clockwise to completion; (J) The excess bands are removed.

Source: Adapted from Wallis Posterior Dynamic Stabilization System: Surgical

compressed into final position. The excess bands are removed (Fig. 6J). A drain is frequently placed, but is ultimately dependent on surgeon's preference and experience. A careful layered closure is performed. The supraspinous ligament is then reattached to its original position on the spinous processes through drill holes placed at the dorsal border of the spinous processes. The lumbodorsal fascia is then approximated and sutured closed. The skin is closed in layered fashion.

COFLEX, COFLEX-F

Under a general anesthesia, the patient is placed in a prone position. Positioning pads are placed to avoid hyperlordosis and achieve either a neutral or semiflexed position in the lumbar spine. Fluoroscopic localization identifies the segment of interest. A 4 cm midline incision is made, centered over the interspace. The paraspinal musculotendinous attachments are elevated from the spinous processes and corresponding lamina. Subperiosteal dissection of the paraspinal muscles allows access to the interspinous space, while preserving the facet capsules (Fig. 7A).

An optional unilateral direct microdecompression can be performed at the surgeon's discretion (Fig. 7B). The supraspinous ligament is subperiosteally dissected off of the tips of the spinous processes and retracted laterally with the

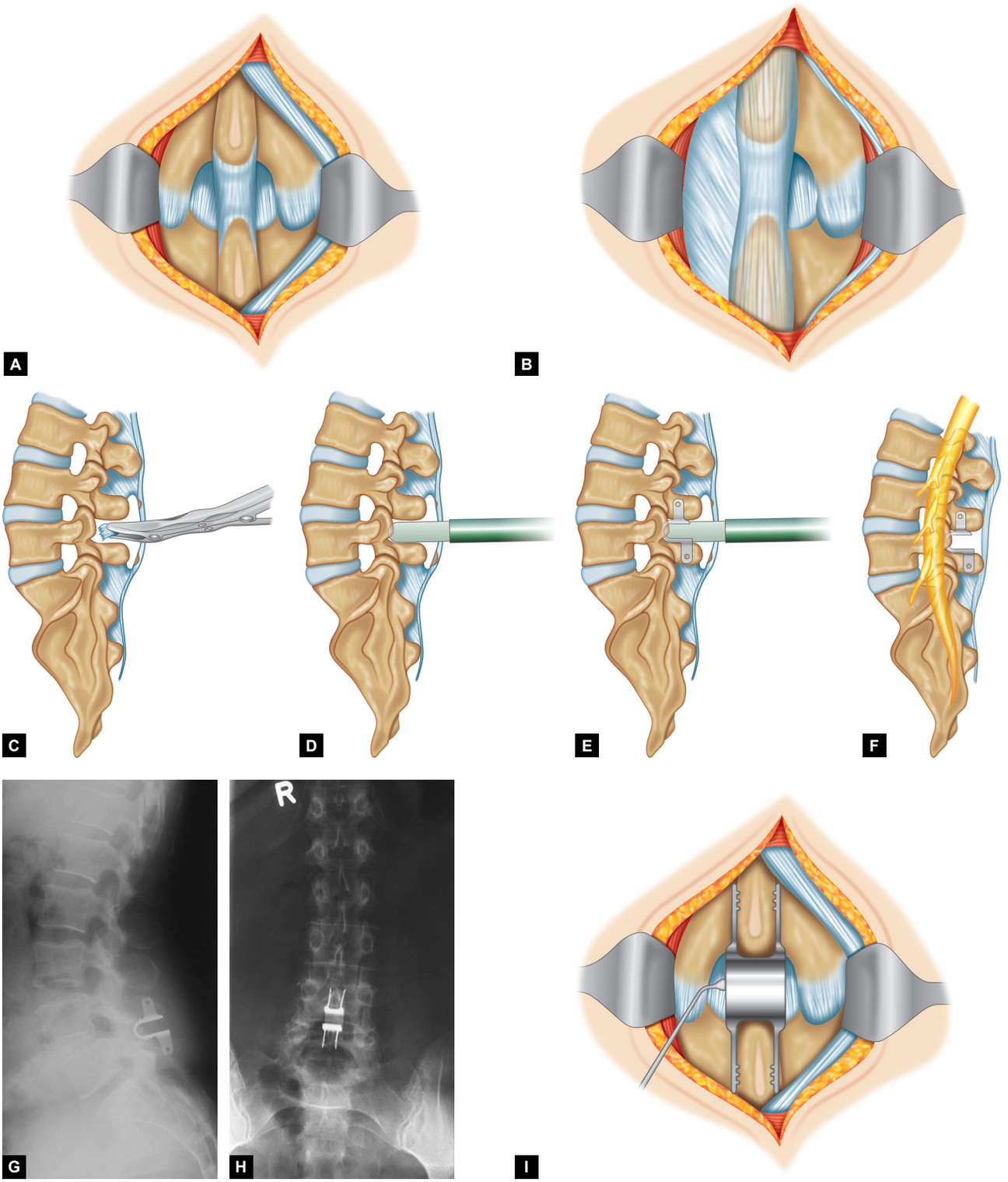

Figs 7A to I

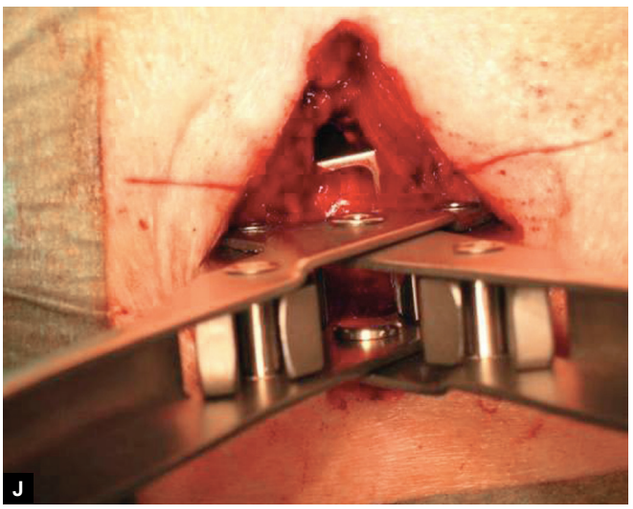

Figs 7A to J: Coflex Technique. (A) After a midline skin incision is performed, the paraspinal musculature is elevated. The supraspinous ligament is preserved, elevated and retracted (to the right as shown); (B) Alternatively, if a unilateral decompression is warranted, the supraspinous ligament together with the fascia and muscle from the opposite side can be mobilized as a whole; (C) The interspinous ligament is resected, in addition to any bony overgrowth of the spinous process; (D) Trials are utilized to define the appropriate size of the implant; (E) The implant is introduced with an inserter; (F to I) Proper depth of insertion is verified fluoroscopically and by passing a beaded tip probe freely between the implant and the dura; (J) If the wings do not have sufficient contact, additional stability can be achieved by crimping the wings. *Source*: Adapted from Coflex: Surgical Technique. Paradigm Spine

contralateral myofascial structures. Care is taken to preserve the supraspinous ligament. If maintenance of the supraspinous ligament is not possible, late reconstruction of the supraspinous ligament is possible in postimplant insertion. The interspinous space is identified, and the interspinous ligament is resected (Fig. 7C).

A series of trials are inserted into the interspinous space from dorsal to ventral to define the appropriate implant size (Fig. 7D). Insertion of the trial implants is aided by distraction of the spinous processes. If the spinous processes are hypertrophic or too thick for implant insertion, the wings of the implant can be bent open with specialized wing-bending pliers. The final implant is then malleted into position (Figs 7E and F). Proper depth is gauged both fluoroscopically and under direct visualization (Figs 7G and H). The implant should be 3–4 mm from the dura. Passing a ball tip probe in this space can help measure this distance (Fig. 7I). The implant should have a press-fit bony contact to the adjacent spinous processes. Further stability is achieved when the wings of the implant are then compressed against the spinous processes with a crimper (Fig. 7J). Again, if necessary, reconstruction of the supraspinous ligament is completed. If multiple levels are treated, the caudal level is treated first. The wings of the implant are staggered to allow successive implants. The supraspinous ligament is reattached to the spinous processes. This can be achieved by placing drill holes in the dorsal aspect of the corresponding spinous processes. A surgical drain may be placed dependent on surgeon experience and intraoperative bleeding. The lumbodorsal fascia is approximated and sutured. The skin is closed in layered fashion.

POSTOPERATIVE CARE

Patients are encouraged to ambulate as soon as they feel comfortable. Patients are to avoid heavy lifting and hyperextension activities for 2–6 months, with a gradual return to activities of daily living. Patients should also avoid hyperextension exercises for this period, specifically if a Coflex has implanted. After any procedure, the patient is encouraged to maintain constant spine health.

COMPLICATIONS

Complications related to implantation of IPDs are few. There are complications associated with undergoing any surgical procedure and complications

Fig. 8: Occult spinous process fracture visualized with sagittal CT imaging. (Adapted from Kim et al. Occult spinous process fractures associated with interspinous process Spacers)

that are specific to each implant. Due to the nature of distraction imparted either during the implanting process or the distraction placed when an extension load is upon the implant, spinous process fracture is an uncommon, but potential complication (Fig. 8).[12] It is possible to fracture the spinous process if too much force is applied to the sizing distractor or when passing an implant. If a fracture compromising the load bearing capacity is encountered intraoperatively, the procedure is simply converted to a laminectomy with or without fusion since the design of the interspinous spacers relies on the integrity of the intact cephalad and caudal spinous processes. The author routinely checks the bone density of hips in all patients preoperatively. In the author's 600 patient experiences with X-STOP, T-scores less than -2.8 are more prone to failure by settling or fracture.

In the US. clinical study for X-STOP, there was one case of traumatic dislodgement.5 This remains an uncommon possibility for each of the implants discussed. Additional rare complications include infections, seroma and wound dehiscence. The most likely unfavorable outcome is failure to relieve the symptoms associated with lumbar spinal stenosis. Revision rates after X-STOP implantation were 6% over 2 years in the study of Zucherman et al.[4] and Siddiqui et al. reported less than 10%.[13] The surgical technique of most of these implants does not require significant alteration in the anatomy, and therefore, does not prevent a secondary, conventional approach.

KEY POINTS

- The initial insertion point is generally at the level of the medial left lamina of the cephalad level being instrumented.
- Use a finger to identify the insertion site of the interspinous space during exchange of instruments.
- Ventral placement of the implant is usually desired (unless the interspinous space has a "V" configuration); this may require partial resection of hypertrophic medial facet processes and osteophytes.
- Preoperative DEXA scan may help guide a surgeon in the amount of distraction placed and the size of the implant inserted.
- The interspinous spacer does not increase slippage in a low grade spondylolisthesis.
- Implantation of an interspinous spacer usually leads to significant pain relief (VAS) and functional restoration (ODI or ZCQ) in properly indicated patients.
- Two years and four years outcome of studies for X–STOP have demonstrated an 85% and 78% success rate, respectively.[5,6]
- X-STOP implant has proven to improve the radiographic parameters of foraminal height, width, and cross-sectional area more than the DIAM and Wallis implants; however, there is no data to determine a statistically significant difference in symptom relief among the three implants. The X-STOP is only recommended and proven for neurogenic intermittant claudication patients. Proof of efficacy and indications for the other implants mentioned is pending.

REFERENCES

1. Infusa A, An HS, Lim TH, et al. Anatomic changes of the spinal canal and intervertebral foramen associated with flexion-extension movement. Spine. 1996;21:2412-20.
2. Penning L, Wilmink JT. Posture-dependent bilateral compression of L4 or L5 nerve roots in facet hypertrophy. A dynamic CT-myelographic study. Spine. 1987; 12:488-500.
3. Zucherman J, Simons P, Timothy J. X STOP interspinous implant for lumbar spinal decompression. Brussels International Spine Symposium. 2005;18-9.
4. Zucherman JF, Hsu KY, Hartjen CA, et al. A prospective randomized multi-center study for the treatment of lumbar spinal stenosis with the X-STOP interspinous implant: 1-year results. Eur Spine J. 2004;13(1):22-31.
5. Zucherman JF, Hsu KY, Hartjen CA, et al. A multicenter, prospective, randomized trial evaluating the X-STOP interspinous process decompression system for the treatment of neurogenic intermittent claudication: two-year follow-up results. Spine. 2005;30:1351-8.
6. Kondrashov DG, Hannibal M, Hsu KY, et al. Interspinous process decompression with the X-STOP device for lumbar spinal stenosis: a 4-year follow-up study. J Spinal Disord Tech. 2006;19:323-7.
7. Richards JC, Majumdar S, Lindsey DP, et al. The treatment mechanism of an interspinous process implant for lumbar neurogenic intermittent claudication. Spine. 2005;30(7):744-9.
8. Kabir SM, Gupta SR, Casey AT. Lumbar interspinous spacers: a systematic review of clinical and biomechanical evidence. Spine. 2010;35(25):E1499-506.
9. Christie SD, Song JK, Fessler RG. Dynamic Interspinous Process Technology. Spine. 2005;30:S73-8.
10. Lindsey DP, Swanson KE, Fuchs P, et al. The effects of an interspinous implant on the kinematics of the instrumented and adjacent levels in the lumbar spine. Spine. 2003;28:2192-7.
11. Nandakumar A, Clark NA, Peehal JP, et al. The increase in dural sac area is maintained at 2 years after X-STOP implantation for the treatment of spinal stenosis with no significant alteration in lumbar spine range of movement. The Spine Journal. 2010;10:762-8.
12. Kim DH, Tantorski M, Shaw J, et al. Occult spinous process fractures associated with interspinous process spacers. Spine Epub;2011.
13. Siddiqui M, Karadimas E, Nicol M, et al. Effects of X-STOP device on sagittal lumbar spine kinematics in spinal stenosis. J Spinal Disord Tech. 2006;19:328-30.

Surgical Technique Guides: DIAM Spinal Stabilization System: Surgical Technique. May 2008 (Version H) P04-08. Medtronic Sofamor Danek.

Coflex TM: Surgical Technique. Paradigm Spine. http://www.ossano.se/Produkter/Ryggimplantat/Coflex/Coflex_surgical_technique.pdf

Wallis Posterior Dynamic Stabilization System: Surgical Technique. Zimmer (Abbott Spine). [online] Available from http://www.zimmer.com/web/enUS/pdf/surgical_techniques/Wallis_Surgical_Technique1.pdf [Accessed December, 2011].